

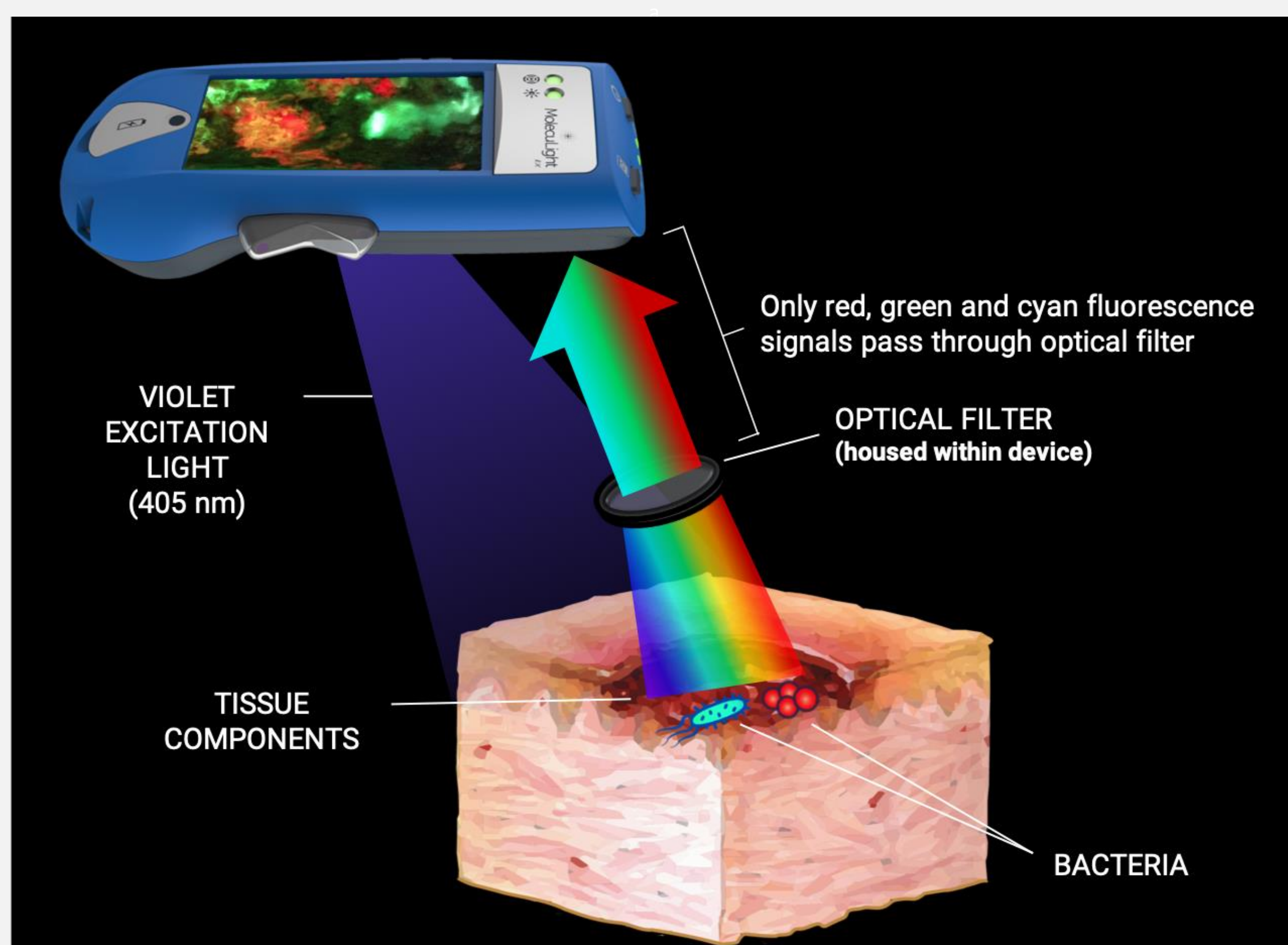
INTRODUCTION

- Wound cleansing to remove surface bacteria is an essential component of wound bed preparation¹.
- It is challenging for clinicians to objectively assess at the point of care the effectiveness of a wound cleanser in removing the surface bacteria.
- Most cleansers are cytotoxic, therefore the provincial health authority of British Columbia, Canada mandated that only normal saline be used².
- Two novel, non-cytotoxic and tissue-compatible wound cleansers were identified by the provincial authority to improve the removal of surface bacteria: a hypochlorous acid solution and a modified sodium hypochlorite solution.
- This study aimed to objectively evaluate and compare the effectiveness of the two novel wound cleansers to substantiate selecting a specific cleanser and switching from normal saline as best practice.

METHODS

Bacterial Fluorescence Imaging (MolecuLight i:X)

- When excited by 405 nm violet light, tissues fluoresce green while bacteria fluoresce red (porphyrin-producers, e.g. *Staphylococcus aureus*) or cyan (pyoverdine-producing *Pseudomonas aeruginosa*).
- This enables real-time, point-of-care detection and localization of bacteria at loads of moderate to heavy within and around wounds³⁻⁵.



Comparison Study

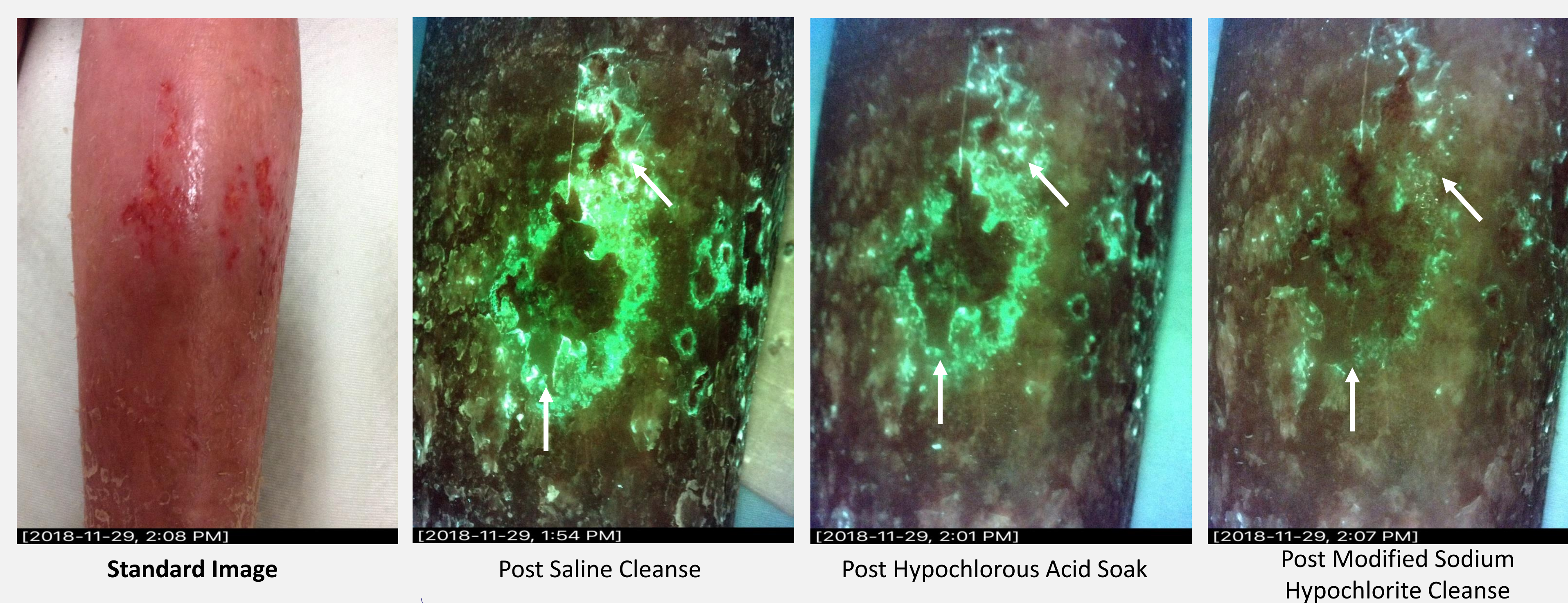
- Wounds (n=15) were cleansed with normal saline, as per best practice, after which a fluorescence image was acquired to visualize any concerning levels of bacteria remaining within and around the wound.
- Wounds were next soaked with the hypochlorous acid for a minimum of five minutes (per manufacturer guidelines), scrubbed and then re-imaged.
- Wounds were lastly sprayed with sodium hypochlorite solution and immediately scrubbed and re-imaged.

RESULTS

Fluorescence Imaging Used to Verify Effectiveness of Cleansers – Example Cases

CASE 1

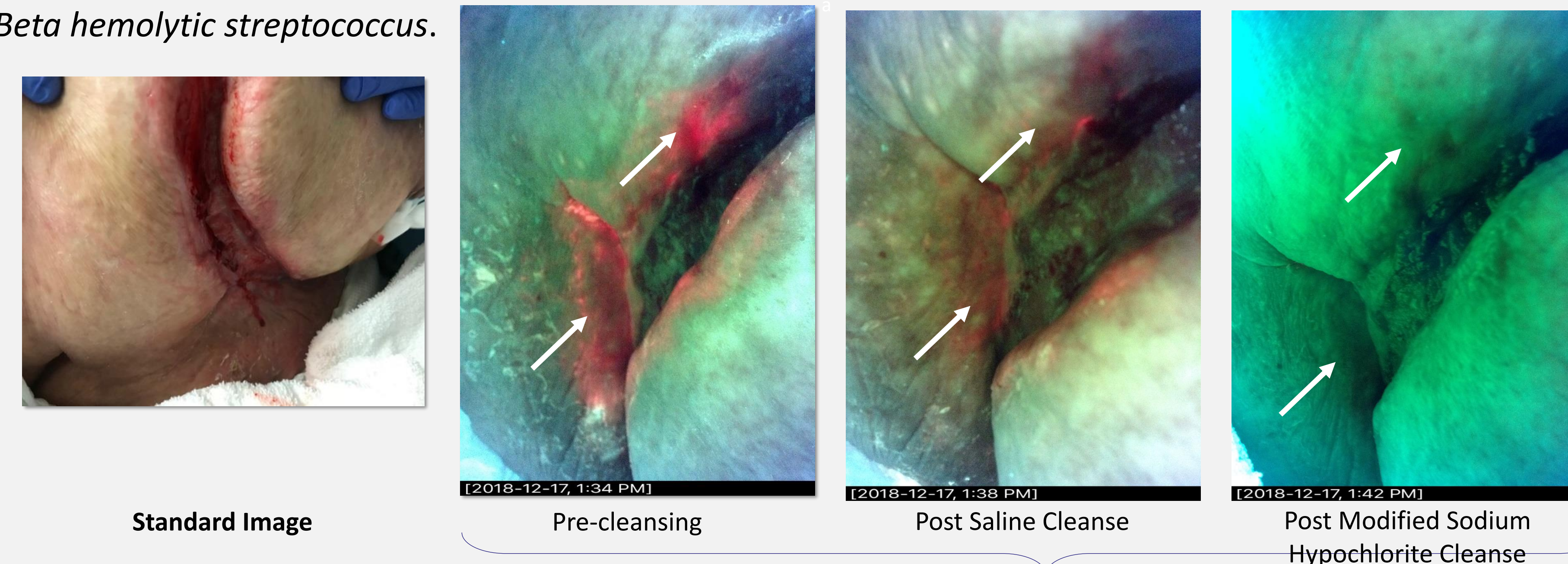
95-year-old man with bilateral lower extremity edema and superficial wounds on the lower leg. Patient comorbidities include chronic kidney disease, hypertension, neuropathy, atrial fibrillation, and coronary artery disease. Cyan fluorescence indicating the presence of *Pseudomonas aeruginosa* was observed after the normal saline cleansing. Cyan fluorescence was only slightly decreased after the 6 minute soak with the hypochlorous solution. Following the 1 minute cleanse with the sodium hypochlorite solution, the cyan fluorescence signal was almost entirely gone.



Fluorescence Images

CASE 2

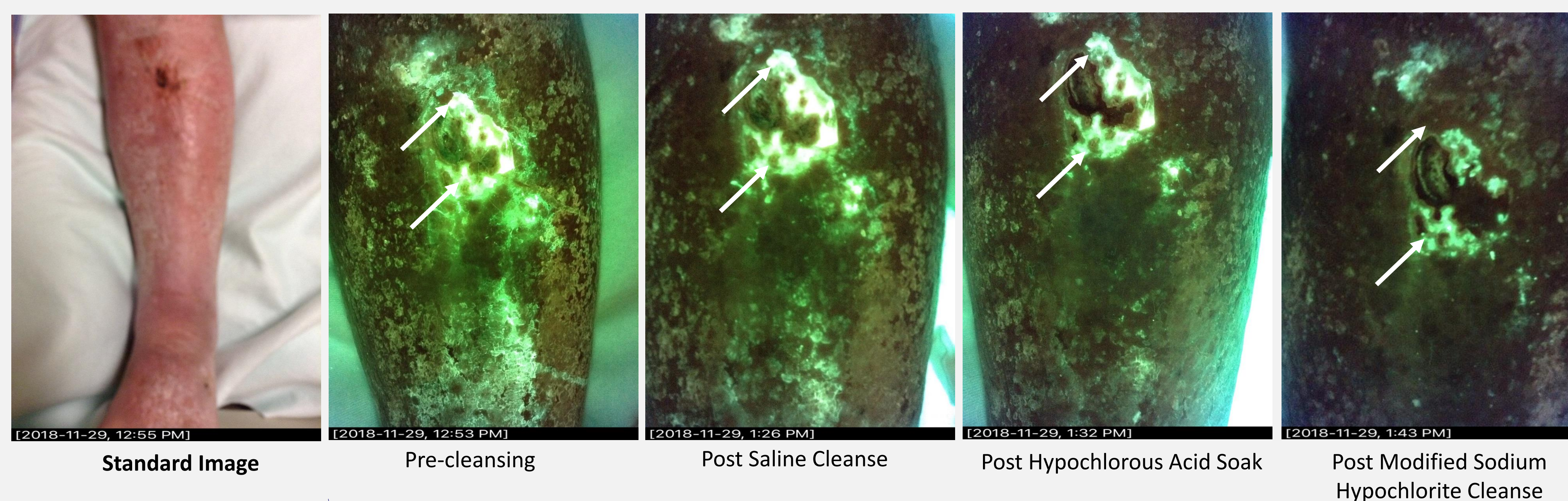
Patient presented with a dehisced flap procedure post pressure injury. Red fluorescence indicating the presence of porphyrin-producing bacteria was observed. Post cleansing with normal saline, a slight decrease in the red fluorescence was observed. After cleansing with the sodium hypochlorite solution, there was no red fluorescence remaining, indicating the cleanser was effective in remove the surface level bacteria. Swabbing results from after the sodium hypochlorite cleanse: Light growth of *Mixed coliforms*, Light growth of *Group B Beta hemolytic streptococcus*.



Fluorescence Images

CASE 3

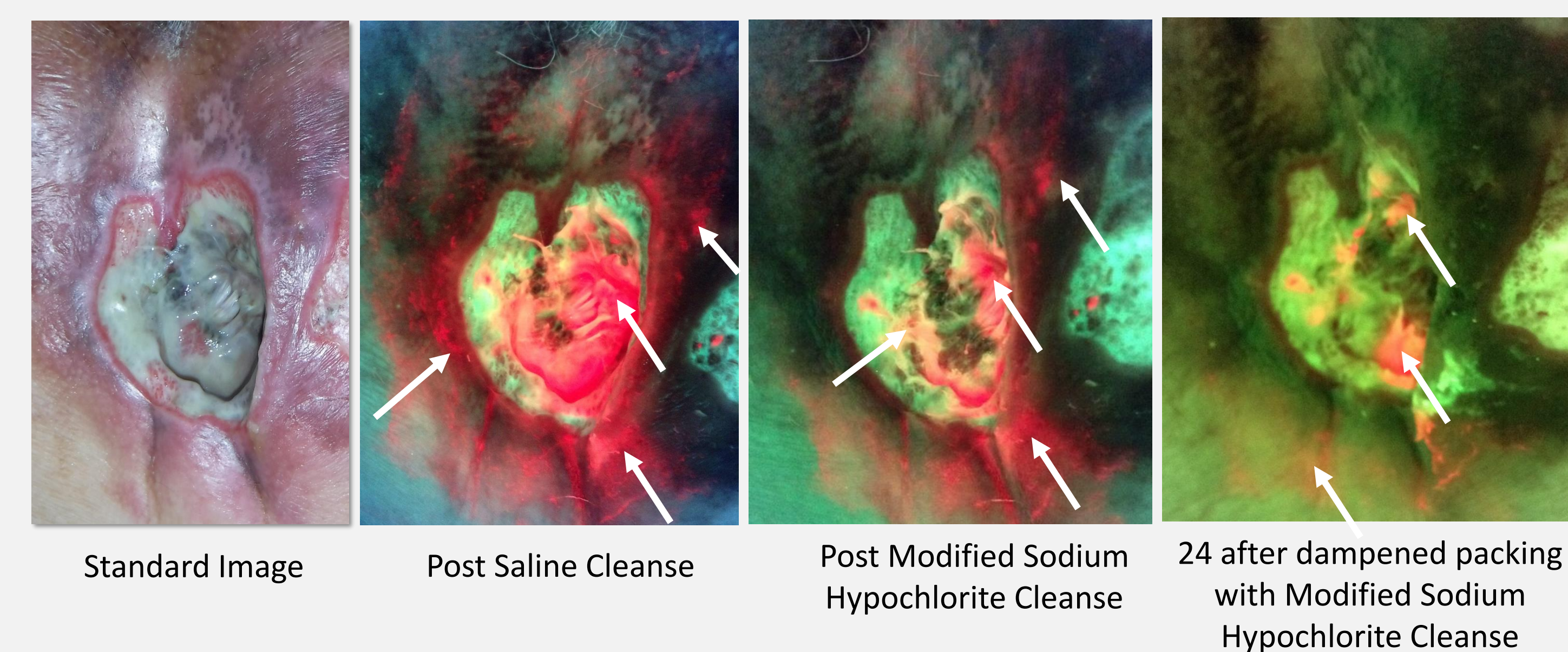
71-year-old admitted to the hospital with sepsis, pneumonia and lower leg wounds with widespread cyan fluorescence was observed. Cyan fluorescence was not significantly decreased post saline cleansing or post 6 minute soak hypochlorous solution cleansing. Following cleansing with sodium hypochlorite solution, the cyan fluorescence was significantly decreased.



Fluorescence Images

CASE 4


91-year-old male pressure injury patient. Widespread red fluorescence was observed in the wound bed and peri-wound, resulting in a culture being taken and an infectious disease consult. A reduction in red fluorescence was observed post cleansing with modified sodium hypochlorite solution (hypochlorous acid soak was not done). A further decrease in red fluorescence was noted after 24 hours of packing with the cleanser. Culture was positive for heavy growth of mixed anaerobes (Beta lactamase positive).



Fluorescence Images

CASE 5

Patient presented with an abdominal wound. A discrete area of cyan fluorescence was observed on the wound periphery. Post cleansing with both normal saline and 5 minute hypochlorous solution soak did not remove the cyan fluorescence. The cyan fluorescence was successfully removed with the sodium hypochlorite solution.



Fluorescence Images

CONCLUSIONS

- Saline cleansing, according to best practice, left behind widespread bioburden in all wounds.
- Heavy bioburden in and around wounds can be identified from the fluorescence images and fluorescence images provide an objective method of evaluating the effectiveness of cleansing and performing targeted cleansing at the point of care.
- The evaluation found that sodium hypochlorite solution was superior to both normal saline and the competitor hypochlorous solution in removing *Pseudomonas* and other bacteria.
- Based on the results, the provincial authority now recommend that wounds exhibiting heavy bioburden be cleansed with sodium hypochlorite solution.

REFERENCES

- Pilcher M. Wound cleansing: a key player in the implementation of the TIME paradigm. J Wound Care (2016)
- British Columbia Provincial Nursing Skin & Wound Committee Procedure: Wound Cleansing (2017)
- DaCosta RS et al. Point-of-Care Auto-fluorescence Imaging for Real-Time Sampling and Treatment Guidance of Bioburden in Chronic Wounds: First-in-Human Results, PLoS ONE 10(3), 2015.
- Wu YC et al. Handheld fluorescence imaging device detects subclinical wound infection in an asymptomatic patient with chronic diabetic foot ulcer: a case report. International Wound Journal, 2015.
- Ottolino-Perry et al. Improved detection of wound bacteria using autofluorescence image-guided wound sampling in diabetic foot ulcers. International Wound Journal (In revisions).