

Please note: These studies may involve findings that exceed the claims currently cleared by the FDA for the product. Bravida Medical is not intending to make performance claims about its product. The intent is to disseminate the scientific literature on these products. We encourage you to read these studies to understand the strengths and limitations of the data. For some claims, Bravida is seeking to broaden the indications with the FDA in the future using data, such as these studies, to provide the substantiation.



# Modified Sodium Hypochlorite Anti-microbial Skin and Wound Gel in Difficult to Heal Wounds

POSTER PRESENTATION AT THE SYMPOSIUM ON ADVANCED WOUND CARE, FALL 2021

Cassidy Finn, DO, Kristin Connors, NP, Jill Eysaman-Walker, DO, CWSP, ABWMS

Catholic Health Advanced Wound Healing Centers  
Mt. St. Marys Center for Hyperbarics and Wound Healing  
Buffalo, Cheektowaga and Lewiston, NY

THREE CASE HISTORIES USING:

Anasept® Antimicrobial Skin & Wound Cleanser and Anasept® Antimicrobial Skin & Wound Gel



## INTRODUCTION:

A chronic wound can be defined as having a physiologically impaired healing cycle secondary to disruption in one of the four stages of wound healing. Chronic wounds and their treatment continue to be a financial burden to the healthcare system, and present a social and psychological burden to affected patients, making timely and effective treatment of utmost importance. The treatment of chronic non-healing wounds are an ever-evolving field with new products and methods of treatment continually under investigation. Proper wound bed preparation, with cleansing of the wound bed and peri-wound to reduce microbial bioburden, is an important step in treatment, as heavy microbial bioburden can inhibit proper wound healing.

## DISCUSSION:

Modified sodium hypochlorite anti-microbial skin and wound gel and cleanser (MSHAMSW gel and cleanser) is a cost effective, physiologically isotonic, and active against MRSA, VRE, fungi and viruses. MSHAMSW gel and cleanser has been shown in several studies to have superiority in removing *Pseudomonas* and other bacterial bioburden compared to other methods in wound bed preparation. Our case studies demonstrate the importance of microbial bioburden control with the use of MSHAMSW gel and cleanser in healing of chronic ulcerations of varying etiologies.

## REFERENCES

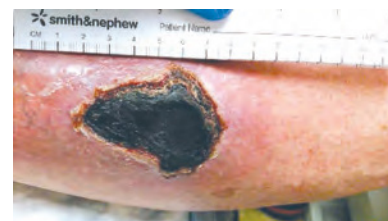Nussbaum SR, Carter MJ, Fife CE, DaVanzo J, Haught R, Nussgart M, Cartwright D. An Economic Evaluation of the Impact, Cost, and Medicare Policy Implications of Chronic Nonhealing Wounds. *Value Health*. 2018 Jan;21(1):27-32. doi: 10.1016/j.jval.2017.07.007. Epub 2017 Sep 19. PMID: 29304937.

Sen CK. Human Wounds and Its Burden: An Updated Compendium of Estimates. *Adv Wound Care (New Rochelle)*. 2019;8(2):39-48. doi:10.1089/wound.2019.0946

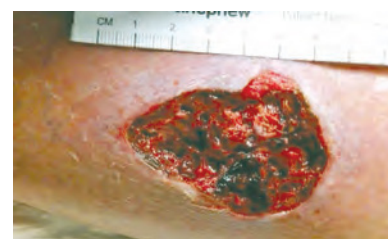## Case #1

R.S. is an 85yo male with past medical history of Type 2 Diabetes, Hypertension, Former Tobacco User, Osteoarthritis, Benign Prosthetic Hypertrophy and Atrial Flutter presenting on 5/18/2021 for evaluation of left lower extremity traumatic ulceration after a fall into a swimming pool leaving a hematoma.

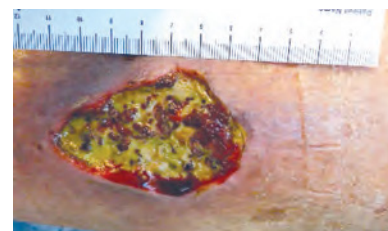
**5/18/21:** Debridement of necrotic tissue.



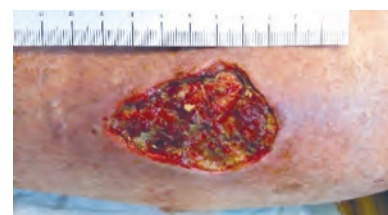
**6/1/21:** Collagenase recommended but too costly. Switch to MSHAMSW G&C.



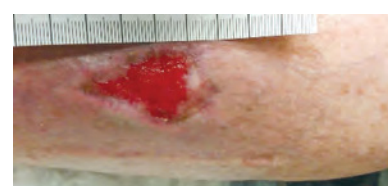**6/16/21:** Vascular evaluation, angiogram scheduled. Continues with MSHAMSW G&C.



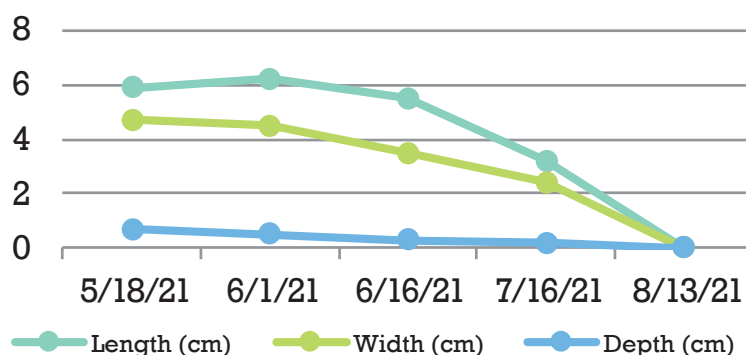
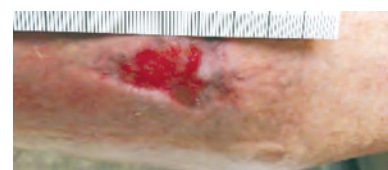
**7/6/21:** Angiogram with no intervention. Single vessel Perineal runoff with total occlusion of Anterior Tibial and Posterior Tibial arteries.



**7/16/21:** Wound continues to improve. Continues with MSHAMSW G&C.



**8/13/21:** Wound achieved 95% closure as of this date and was lost to follow up.





## Case #2

C.W. is a 53yo female with past medical history of Ankylosing Spondylitis, Osteoarthritis, Fibromyalgia, OSA. Asthma and Morbid Obesity presenting on 5/6/2021 for evaluation of right lower extremity ulcerations after several bouts of cellulitis starting in December 2020, with multiple antibiotic courses.

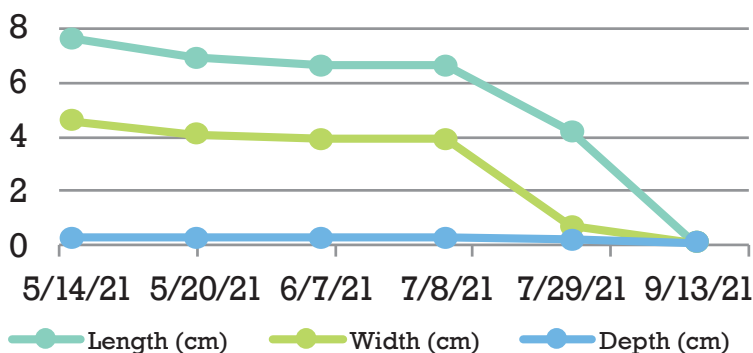
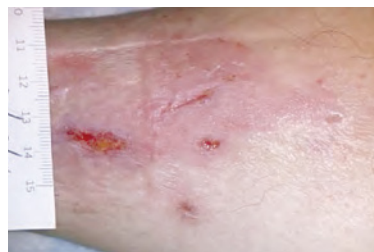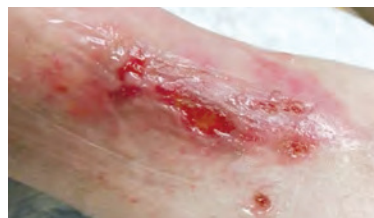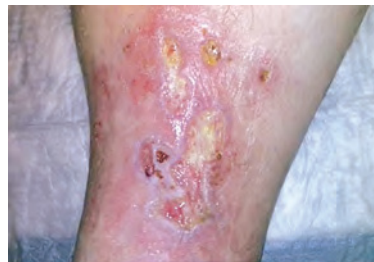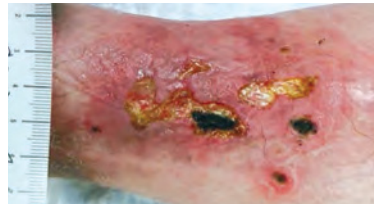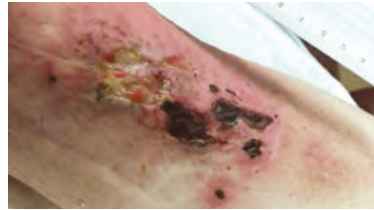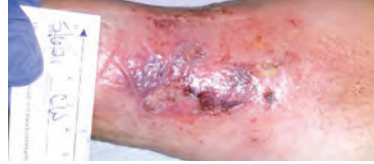**5/6/21:** Ddx includes Pyoderma Gangrenosum due to violaceous borders and pain; steroid course prescribed.

**5/14/21:** On Bactrim. Switch to MSHAMSW G&C.

**5/20/21:** Enbrel started by rheumatology.

**6/7/21 through 7/29/21:** Wound improving and less painful.

**9/13/21:** Wound closure achieved.



## Case #3

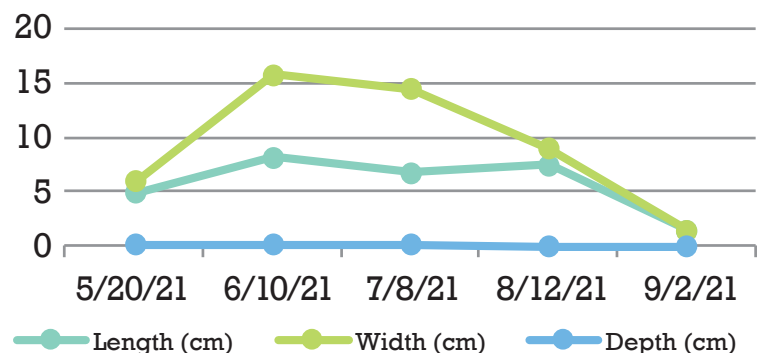
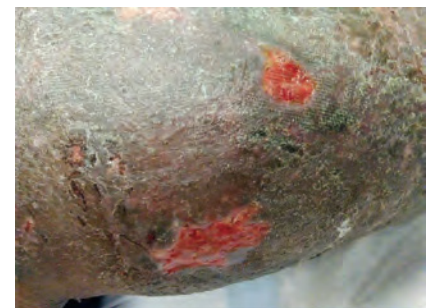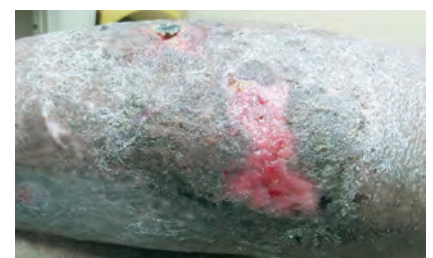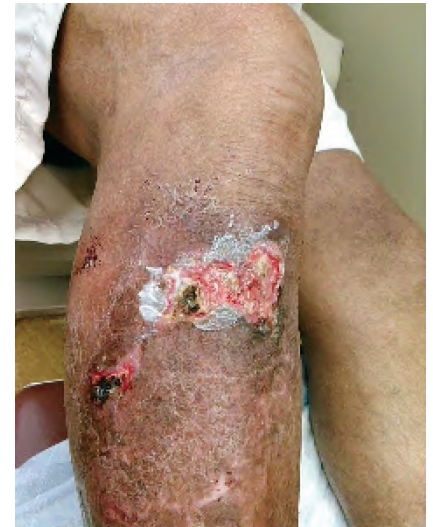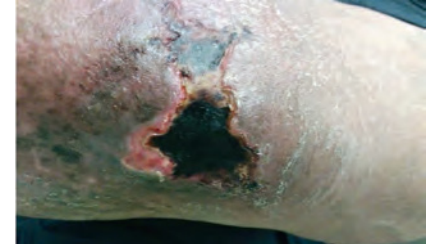C.G. is a 62yo male with past medical history of Pyoderma Gangrenosum, Venous Insufficiency and Obesity presenting on 5/6/2021 for evaluation of a right lower extremity ulceration after sustaining a fall resulting in hematoma formation and subsequent eschar on first evaluation.

**5/20/21:** Black eschar remains. Switch to MSHAMSW G&C.

**6/20/21:** Black Eschar is unstable and able to be deroofed at this visit.

**7/8/21:** Ulceration continues to improve.

**8/12/21:** Ulceration with healthy granulation tissue. Switch to collagen dressing.



# anasept<sup>+</sup>



ordering information:

## Anasept<sup>®</sup> Antimicrobial Skin & Wound Cleanser

CATALOG NO.		NDC NUMBER	SIZE	CASE QUANTITY
4004C	(Dispensing Cap)	67180-400-04	4 oz	24
4008C	(Dispensing Cap)	67180-400-08	8 oz	12
4004SC	(Sprayer)	67180-400-44	4 oz	12
4008SC	(Sprayer)	67180-400-88	8 oz	12
4008TC	(Trigger Sprayer)	67180-408-88	8 oz	12
4012SC	(Trigger Sprayer)	67180-400-12	12 oz	12
4016C	(Dispensing Cap)	67180-400-16	15 oz	12

**Health Canada License #97043**

## Anasept<sup>®</sup> Antimicrobial Skin & Wound Gel

CATALOG NO.		NDC NUMBER	SIZE	CASE QUANTITY
5015G	(Tube)	67180-500-15	1.5 oz	12
5003G	(Tube)	67180-500-03	3 oz	12

**Medicare Reimbursement HCPCS Code # A6248      Health Canada License #97167**



Toll-Free: 888.508.2872 • [www.curasurgical.com](http://www.curasurgical.com)  
e-mail: [customerservice@curasurgical.com](mailto:customerservice@curasurgical.com)



2571 Kaneville Court  
Geneva, IL 60134  
Toll-Free: 888.508.2872  
Fax: 630-232-8005

e-mail: [customerservice@curasurgical.com](mailto:customerservice@curasurgical.com)

**Cura Surgical is an ISO 13485 Certified Company**

Anasept products are manufactured in the USA.