

Please note: These studies may involve findings that exceed the claims currently cleared by the FDA for the product. Bravida Medical is not intending to make performance claims about its product. The intent is to disseminate the scientific literature on these products. We encourage you to read these studies to understand the strengths and limitations of the data. For some claims, Bravida is seeking to broaden the indications with the FDA in the future using data, such as these studies, to provide the substantiation.

Research Article

OPEN

Use of a Silver Nylon Dressing Following Total Hip and Knee Arthroplasty Decreases the Postoperative Infection Rate

Ashley J. Tisosky, MD
Otatade Iyoha-Bello, BSc
Nicholas Demosthenes, BA
Giovanni Quimbayo, MD
Tara Coreanu, BSc
Ayesha Abdeen, MD, FRCSC

From the Department of Orthopaedic Surgery, Harvard Combined Orthopaedic Residency Program, Massachusetts General Hospital, Boston, MA (Dr. Tisosky); the Department of Orthopaedic Surgery (Ms. Iyoha-Bello and Dr. Quimbayo) and the Department of Health Care Quality (Mr. Demosthenes), Beth Israel Deaconess Medical Center, Boston; the Faculty of Health Sciences, Clinical Research Center, Soroka University Medical Center, Ben-Gurion University of the Negev, Beer-Sheva, Israel (Ms. Coreanu); and the Department of Orthopaedic Surgery, Harvard Medical School, Beth Israel Deaconess Medical Center, Boston (Dr. Abdeen).

JAAOS Glob Res Rev 2017;1:e034

DOI: 10.5435/
JAAOSGlobal-D-17-00034

Copyright © 2017 The Author(s). Published by Wolters Kluwer Health, Inc. on behalf of the American Academy of Orthopaedic Surgeons. This is an open-access article distributed under the terms of the Creative Commons Attribution-Non Commercial-No Derivatives License 4.0 (CCBY-NC-ND), where it is permissible to download and share the work provided it is properly cited. The work cannot be changed in any way or used commercially without permission from the journal.

Abstract

Introduction: Prosthetic joint infection (PJI) is a potentially catastrophic complication of total joint replacement. Our purpose was to determine whether the use of a silver dressing reduces the incidence of superficial and deep PJI following primary total hip replacement and total knee replacement.

Methods: A case-control study of primary total hip replacement and total knee replacement was performed to compare the incidence of superficial and deep PJI in patients who received a silver nylon dressing with patients who received a standard dressing.

Results: The incidence of infection was significantly lower in the study group compared with the control group. There were no deep PJIs in the silver dressing group. Twelve patients (2.3%) in the control group developed PJI.

Discussion: The use of a silver dressing significantly reduced the incidence of superficial and deep PJI following total joint replacement ($P = 0.010$). Given the financial impact of PJI, the application of silver dressings may result in considerable cost savings, and a formal cost-benefit analysis could be investigated.

Prosthetic joint infection (PJI) is a potentially catastrophic complication of total hip replacement (THR) and total knee replacement (TKR) surgeries that is associated with significant morbidity and mortality.¹ Infection is the most common cause of failure of TKR surgery and the third most common cause of failure following THR surgery.^{2,3} The treatment of PJI often necessitates prolonged antimicrobial regimens and repeat surgical procedures that may include temporary or permanent removal of the

implant.^{4,5} Despite contemporary treatment protocols, the incidence of PJI continues to rise. In the setting of multidrug-resistant organisms and immunocompromised hosts, these infections may result in loss of limb or life resulting from sepsis.

Because the number of patients having arthritis of the hip and knee continues to rise, the numbers of joint replacements are projected to increase 673% and 174% by the year 2030 for primary TKR and THR, respectively.⁶ This would amount to approximately 4 million total joint

replacements (TJR) performed each year. Although the rate of infection reported following TJR is low (0.58%–2.4%), the increase in the volume of TJR procedures has resulted in 5,310 to 21,240 infections per year.⁷ As the magnitude of patient suffering increases, so does the economic burden associated with prolonged antibiotic treatments, repeat surgical procedures, and extended admissions to hospital and postacute care facilities, as well as lost wages because of prolonged patient disability.⁸ The financial impact of PJI in the United States was \$566 million in 2009 and is projected to increase to \$1.62 billion in 2020.⁹ Strategies to reduce the incidence of deep PJI are imperative.

The antimicrobial properties of silver ion have been known for centuries. Historically, topical silver was used in the 1800s in the treatment of infected traumatic battle wounds, burns, venereal diseases, and leg ulcers.¹⁰ The recent increase in infections resulting from resistant microorganisms has led to the development of contemporary silver ion-containing dressings designed to treat and prevent infections. Silver-impregnated dressings have been shown to be safe and effective in reducing the incidence of surgical site infections (SSIs) following colorectal, cardiothoracic, lumbar spine, and foot and ankle surgeries.^{11–14} A retrospective study has also shown silver-impregnated dressings to reduce infection risk following cesarean sections.¹⁵ Others have shown silver dressings to be associated with improved wound analgesia and incisional cosmesis.¹⁶ A retrospective review of patients who underwent TJR with the use of a silver dressing (Aquacel Ag with Hydrofiber; Convatec) demonstrated

a significant reduction in the incidence of acute PJI compared with a standard nonsilver dressing.¹⁷

To our knowledge, the performance and efficacy of a silver nylon dressing (Silverlon) as it pertains specifically to the incidence of PJI following primary THR and TKR surgeries have not been evaluated in a nonindustry-supported study. We sought to determine whether the use of a silver nylon dressing reduces the incidence of both superficial infection and deep PJI within 1 year following primary THR and TKR surgeries and whether this dressing can be used safely in this patient population.

Methods

A case-control study was conducted for quality assurance purposes to evaluate the efficacy of a silver nylon dressing (Silverlon Island Dressing) in patients who presented to our institution for primary THR and TKR surgeries. The study group was followed prospectively and compared with historic controls. Permission to perform this quality assurance study was granted by the institutional review board.

Inclusion criteria included all male and female patients aged 18 years and older who were consecutively scheduled to undergo primary TKR and THR surgeries. Patients were treated by two surgeons at a single institution. Exclusion criteria included revision THR and TKR, bilateral joint replacement, and prior or active infection of the operative extremity. Patient characteristics were collected, including age at surgery, sex, tobacco use, body mass index, and immunocompromised status. Patients were considered to be immunocompromised when they had uncontrolled diabetes, pres-

ence of HIV, liver disease, active cancer with ongoing chemotherapy, and/or latent tuberculosis, or were currently using corticosteroids or methotrexate. Current steroid use, diabetes, presence of HIV, and liver disease were also evaluated as independent risk factors for infection. Patients' surgical risk was measured using the American Society of Anesthesiologists (ASA) physical status classification (ASA 1 or 2 as low risk and ASA ≥ 3 as high risk).¹⁸

This study consisted of two groups. The study group received a Silverlon dressing at the time of surgery and consisted of all patients who had primary THR and TKR between 2013 and 2014 after both surgeons started to use silver-impregnated dressings for all TJR cases. The Silverlon dressing was placed on the incision at the time of surgery and removed on the seventh postoperative day, as recommended by the manufacturer. Dressings that were saturated prior to this time frame were replaced with a second Silverlon dressing that was also removed on the seventh postoperative day, as initially scheduled. The control group consisted of all patients who had primary THR and TKR performed by the same two surgeons from 2011 to 2013, prior to the time the surgeons started to use the silver-impregnated dressing. The patients in the control group received what will be referred to as a "standard" dressing consisting of a non-adherent layer (Xeroform) and dry gauze. The standard dressing was changed to a second standard dressing on postoperative day 2 and then changed daily until the wound remained dry.

All surgical incisions were treated with a primary closure using staples in the skin and a sterile dressing placed at the time of surgery. The

None of the following authors or any immediate family member has received anything of value from or has stock or stock options held in a commercial company or institution related directly or indirectly to the subject of this chapter: Dr. Tisosky, Ms. Iyoha-Bello, Mr. Demosthenes, Dr. Quimbayo, Ms. Coreanu, and Dr. Abdeen.

postoperative protocol was consistent between both surgeons and compliant with an institutional standardized protocol for all patients undergoing TJR. All patients received perioperative antibiotics, specifically cefazolin 2 g intravenous (IV) Q8H for a 24-hour period. Patients with a body weight greater than 100 kg were given cefazolin 3 g IV Q8H for a 24-hour period. Patients who had a penicillin allergy or a positive methicillin-resistant *Staphylococcus aureus* preoperative nasal swab screening were administered vancomycin 15 mg/kg IV Q12H for a 24-hour period. Venous thromboembolism (VTE) prophylaxis was accomplished with enoxaparin subcutaneously for 4 weeks postoperatively in all patients. Patients received a dose of tranexamic acid 10 mg/kg preoperatively unless contraindications were present. Contraindications for tranexamic acid administration at our institution are as follows: a glomerular filtration rate <60 mL/min, known colorblindness, history of deep vein thrombosis or pulmonary embolism, known thrombophilia (including, but not limited to, factor V Leiden and protein S or C deficiency), and anesthesiologist concern regarding specific coagulation issues, commonly including recent stroke, myocardial infarction, or multiple intracoronary stents. All patients received low-molecular-weight heparin for prevention of VTE. If low-molecular-weight heparin was contraindicated, VTE prophylaxis was in the form of warfarin. All patients participated in physical therapy starting on postoperative day 1 and continued a standardized regimen postoperatively. All patients had staples removed 2 weeks postoperatively.

Study patients were followed prospectively to determine the onset of superficial infection (including wound infection, stitch abscess, and cellulitis) and deep PJI. These data were ex-

tracted retrospectively for the control group based on chart review. Data were collected until the 12-month annual follow-up visit for all study and control subjects. Diagnosis for deep PJI was based on the criteria defined by the workgroup convened by the Musculoskeletal Infection Society.¹⁹ Patients with deep PJI were further subcategorized into acute deep PJI, defined as <3 weeks between symptom onset and treatment, and chronic PJI, defined as >3 weeks between symptom onset and treatment.⁴ The diagnosis of superficial infection was made by the treating surgeon and included superficial incisional infections (wound drainage, erythema, or dehiscence), stitch abscesses, and cellulitis (acute erythema extending beyond the limits of the surgical wound on the operative extremity). The decision to aspirate the knee to rule out the presence of deep PJI in the setting of a wound complication or cellulitis was left to the discretion of the treating surgeon and was based on the presence of joint pain with range of motion, active drainage, fever, and/or elevated serum inflammatory markers.

Statistical Analysis

The primary outcome measure of this study included the combined rate of postsurgical superficial and deep infections that occurred within 1 year following surgery. Secondary outcomes included the individual incidence of deep and superficial infections. Subgroup prespecified analysis included analysis by immunocompetence status. Continuous variables with normal distribution are presented as mean (\pm SD) and compared using the Student *t*-test. Continuous variables with non-normal distributions are presented as medians and interquartile ranges and compared using the Mann-Whitney test. Dichotomous or nominal categorical variables are compared with

the use of the chi-square test with normal approximation or Fisher exact test, as appropriate.

We used a generalized estimating equation (GEE) approach for the univariate and multivariate analyses of the outcomes to account for the individual surgeon clustering. We used an interchangeable correlation matrix and logistic regression as a link function. The variables were introduced to the model based on the clinical and statistical significance ($P < 0.1$ in univariate analysis). The final model included the following variables: patient age at the time of surgery, ASA class (ASA 1 or 2 as low risk and ASA ≥ 3 as high risk), immunocompromised status, and the use of a silver dressing.

In a subgroup analysis among those who had any infection, superficial infection and deep infection were stratified by the immunocompetence status. A univariate logistic regression model using GEEs to account for the individual surgeon clustering was used to calculate odds ratios (ORs) and 95% confidence intervals (CIs).

Statistical analysis was performed using IBM SPSS Statistics software package (version 20.0; IBM). Two-tailed values of $P < 0.05$ were considered statistically significant.

Results

The study group consisted of 309 consecutive TJR cases performed in 309 patients (219 TKRs and 90 THRs) from November 1, 2013, to November 30, 2014. The control group consisted of 525 consecutive TJRs performed in 525 patients (382 TKRs and 143 THRs) who underwent surgery from November 1, 2011, to November 30, 2013. The study and control patients were compared with respect to demographics and risk factors for infection (Table 1). There were no patients who were

Table 1**Baseline Characteristics of the Patients**

Population Characteristics	No Silver: 62.9% (n = 525)	With Silver: 37.1% (n = 309)	P
Age at surgery, yrs, mean \pm SD	63.40 \pm 10.98	62.53 \pm 11.57	0.280
Sex			0.136
Female, % (n)	62.9 (330)	68 (210)	—
Male, % (n)	37.1 (195)	32 (99)	—
ASA high score (3–5), % (n)	51 (268)	46.3 (143)	0.183
Tobacco use, % (n)	13.9 (73)	21.7 (67)	0.004
Body mass index, median (interquartile range)	31 (27–36)	31 (27–36.5)	0.814
Immunocompromised, % (n)	41.9 (220)	31.7 (98)	0.003
Steroids, % (n)	3.4 (18)	2.6 (8)	0.500
Diabetes, % (n)	27 (142)	20.4 (63)	0.031
HIV, % (n)	2.7 (14)	1 (3)	0.094
Liver disease, % (n)	7.2 (38)	6.5 (20)	0.675

Table 2**Clinical Outcomes**

Outcome	No Silver: 62.9% (n = 525)	With Silver: 37.1% (n = 309)	P
Infection, % (n)	8.4 (44)	3.9 (12)	0.012
Infection type			0.010
Deep infection, % (n)	2.3 (12)	0 (0)	—
Superficial infection, % (n)	6.1 (32)	3.9 (12)	—
Treatment			0.032
Medical alone, % (n)	5.9 (31)	3.2 (10)	—
Surgery, % (n)	2.5 (13)	0.6 (2)	—
Expired patients, % (n)	2.5 (13)	1 (3)	0.126

lost to follow-up at the final follow-up interval of 12 months in either the control group or the study group.

The incidence of any infection was significantly lower in the silver dressing group in comparison with the control group (Table 2). There were no deep PJIs in the group treated with the silver nylon dressing. There were 12 deep PJIs (2.3%) in the control group, including 11 TKRs and 1 THR. The interval from the date of surgery until the onset of infection was a median of 58 days (range, 11–147 days). Most deep infections were acute infections that presented within 3 weeks of the onset of symptoms⁴ (Figure

1). All cases of deep PJI were treated surgically and received parenteral antibiotic treatment: eight required irrigation and débridement with liner exchange and four required two-stage revision. The organisms isolated included the following: methicillin-susceptible *S aureus*, *Corynebacterium*, *Streptococcus viridans*, *Mycobacterium tuberculosis*, *Aggregatibacter*, *Pseudomonas aeruginosa*, *Peptostreptococcus*, and mixed flora (*Proteus mirabilis* and *Enterobacter cloacae*). No organisms were identified in four cases.

There were a total of 46 superficial infections, including 12 in the study group (3.9%: 10 TKRs and 2 THRs)

and 32 in the control group (6.1%: 28 TKRs and 4 THRs). The types of superficial infection are displayed in Figure 2. In all cases of superficial infection, the clinical signs of infection resolved following a course of oral antibiotic treatment. At final follow-up, none of the superficial infections recurred or progressed to deep PJI.

The ORs for the tested variables are summarized in Table 3. The odds of any infection were significantly less in the silver dressing group compared with the control group (OR, 0.382; 95% CI, 0.250–0.583; $P < 0.0001$), as were the odds of superficial infection (OR, 0.546; 95% CI, 0.343–0.870; $P = 0.011$). The odds of any infection, as well as superficial infection, were lower in the silver dressing group in both immunocompetent and immunocompromised patients.

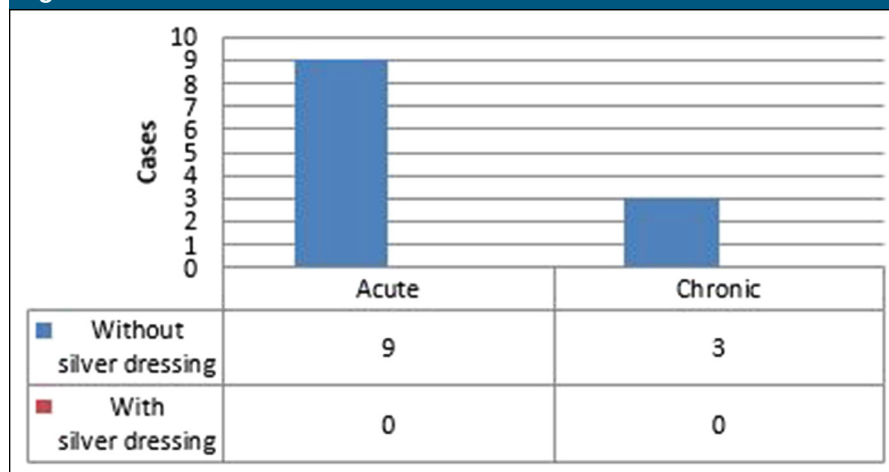
The results of a GEE logistic regression analysis are displayed in Table 4. The odds of any infection were significantly less with the use of a silver dressing, independent of immunocompromised status high ASA score, and age at surgery (OR, 0.396; 95% CI, 0.273–0.573; $P < 0.001$).

Discussion

Infection following THR and TKR surgeries is a devastating complication with tremendous implications pertaining to patient morbidity and mortality. This is further compounded by the astronomical health care costs associated with the treatment of PJIs. As the number of joint replacements performed in the United States continues to rise, so do the numbers of patients affected by infection. The downstream effects of these infections on patients' lives include poor functional outcome and disability, patient dissatisfaction, lost wages because of work absence, and general depreciation in health-related quality of life. To circumvent the adverse effects of PJI, prevention is paramount.

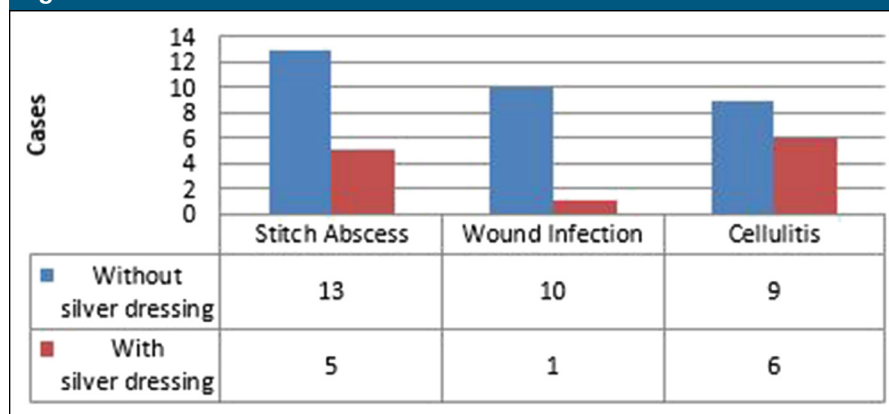
Silver nylon dressings have been found to reduce SSI in a number of surgical procedures, including cardiothoracic surgery, colorectal surgery, cesarean sections, spinal surgery, and recently in the field of arthroplasty.^{11–16} These prior reports have shown that silver ion dressings are safe to be used in the surgical setting and are furthermore effective in reducing SSI. In a prior retrospective study, the use of a dressing that combines silver with hydrofiber layer that gels on contact with the wound (Acquacel Hydrofiber) was found to reduce the incidence of acute PJI following hip and knee arthroplasty.¹⁷ We sought to determine whether a silver nylon dressing can reduce SSI following THR and TKR. The Silverlon dressing differs from the Acquacel dressing in silver content (546 mg/100 cm² versus 8.3 mg/100/cm², respectively) and absence of the hydrofiber gel layer. The silver ion is in direct contact with the skin in the Silverlon dressing, unlike other contemporary silver-containing dressings, and thus we sought to determine

Figure 1



Deep infection type.

Figure 2



Superficial infection type.

whether this dressing with more than 5-fold increased silver content, and direct silver contact with the skin, could be used safely in this population. Furthermore, at our institution, the Silverlon dressing was less expensive than Acquacel (\$30 per dressing versus \$39 of the similar size).

Our study found that the use of a silver nylon dressing significantly reduced the incidence of both superficial infection and deep PJI following THR and TKR in all subjects. The odds of any infection were all significantly lower in the silver nylon dressing group. The strengths of this study include its prospective nature,

use of a control group, and follow-up duration of 1 year. We did not identify any adverse reaction to the silver dressing in our population. This article is the first to our knowledge to evaluate the effect of a silver nylon dressing on SSI following TJR surgery of the hip and knee in a nonindustry-supported study. Furthermore, this is the first study to specifically investigate the use of the Silverlon dressing in this patient population.

Superficial wound infections have been demonstrated to be a risk factor for deep prosthetic infection.^{20,21} It stands to reason that topical agents

Table 3**Association Between the Use of Silver Dressing and Any Infection, Superficial Infection, Deep Infection: Results of a Univariate Logistic Regression Stratified by the Immune Status**

Subjects	Type of Infection	No Silver, 62.9% (n = 525)	With Silver, 37.1% (n = 309)	P	Odds Ratio for Infection (With Silver) and 95% CI
All subjects	Any infection	8.4 (44)	3.9 (12)	<0.0001	0.382 (0.250–0.583)
	Deep infections	2.3 (12)	0 (0)	0.007	—
	Superficial infections	6.1 (32)	3.9 (12)	0.011	0.546 (0.343–0.870)
Immunocompetent: N = 59.1% (305) and N = 40.9% (211), without and with silver	Any infection	7.5 (23)	3.3 (7)	0.016	0.327 (0.131–0.811)
	Deep infections	1.3 (4)	0 (0)	0.149	—
	Superficial infections	6.2 (19)	3.3 (7)	0.083	0.413 (0.152–1.123)
Immunocompromised: N = 69.2% (220) and N = 30.8% (98), without and with silver	Any infection	9.5 (21)	5.1 (5)	<0.001	0.543 (0.492–0.600)
	Deep infections	3.6 (8)	0 (0)	0.113	—
	Superficial infections	5.9 (13)	5.1 (5)	0.301	0.935 (0.824–1.061)

The values in parentheses are the number of subjects in that category.
CI = confidence interval.

Table 4**Association Between the Use of Silver Dressing and Any Infection: Results of a Multivariate Logistic Regression**

Population Characteristics	Odds Ratio	95% CI	P
Age at surgery, yrs	0.989	0.975–1.002	0.102
Immunocompromised	1.304	1.092–1.556	0.003
ASA high score (3–5)	1.390	0.944–2.047	0.095
Silver dressing	0.396	0.273–0.573	<0.001

CI = confidence interval.

aimed at reducing superficial infections may in turn prove to successfully decrease the incidence of PJI. In this study, the use of a silver nylon dressing was associated with significantly lower odds of developing a superficial wound infection compared with a traditional dressing. The use of silver-impregnated dressings has been shown to improve the length of the primary dressing wear time, decrease the number of dressing changes, decrease the length of hospital stay, and avoid skin blistering.²² Although the beneficial effects of silver dressing use are multifactorial, minimizing the risk of superficial wound complications

is likely a major step toward lessening the risk of subsequent PJI.

As expected, immunocompromised patients displayed higher odds of developing any infection following THR and TKR compared with immunocompetent individuals. However, there were no deep infections in any study patients, including immunocompromised patients. Although the control group contained significantly greater immunocompromised patients (Table 1), a multivariate logistic regression analysis determined that the use of a silver nylon dressing was independently associated with significantly lower odds of developing postoperative infection following TJR,

regardless of the immunocompetence or ASA score (Table 4).

The organisms isolated in the cases of deep PJI were nearly all atypical pathogens. Gram-positive cocci are the most common pathogens typically involved in hip and knee PJI. *S aureus* and coagulase-negative *Staphylococcus* account for 50% to 60% of PJIs, whereas streptococci and enterococci contribute to approximately 10% of cases.²³ In our series, only one case of deep PJI had cultures that grew methicillin-sensitive *S aureus*. Furthermore, most of the patients with deep infections were immunocompromised subjects. We attribute the atypical organisms isolated in the cases of deep PJI to the greater number of immunocompromised and complex patients cared for at our tertiary care center. Four of 12 patients with deep PJI had cultures that yielded no growth. This is consistent with previous reports in the literature, in which 5% to 34% of PJIs were found to be culture negative.^{24,25}

The cost per unit of silver dressing exceeds that of a standard dressing (\$30 for Silverlon versus approximately \$2 for a standard gauze dressing). The cost of medical and

surgical treatment for 1 patient with PJI is estimated between \$30,000 and \$70,000.^{26,27} Thus, the use of silver-impregnated dressings at the time of primary THR and TKR may result in considerable cost savings. A cost-benefit analysis is beyond the scope of the current study and could be the subject of future investigation.

Our study is limited because of the short follow-up duration; however, our follow-up interval is sufficient to detect early PJI, which was the primary intent of the study. A longer follow-up duration would be needed to determine the effect of silver dressings on late PJI. Another limitation is the lack of randomization of patients to specific treatment arms. The study groups were generated based on the initiation of silver dressing use in our institution. Although the burden of illness associated with PJI is substantial and the overall national prevalence of PJI continues to rise, the overall infection rates of PJI remain low and are typically in the range of 0.5% to 2%. Thus, our sample size in a single institution may not have been sufficiently large to detect significant differences with certain subgroups, such as the ASA score. This study was conducted as a quality assurance assessment in our specific patient population, and thus results may not be generalizable to the population as a whole.

In conclusion, we demonstrated a significant decrease in superficial and deep PJIs associated with the use of the Silverlon silver nylon dressing in primary total hip and knee arthroplasty. To our knowledge, this is the first non-industry-supported report on the use of silver-impregnated dressings in joint replacement surgery and the first to specifically investigate the use of the Silverlon dressing. We hope that this study will serve as a pilot to facilitate a power calculation for a subsequent multicentered randomized controlled trial to further evaluate the efficacy of silver dressings in total hip and knee arthroplasty.

Acknowledgments

The authors acknowledge Dr. Robert G. Davis for the involvement of his patients in the study.

References

- Lamagni T: Epidemiology and burden of prosthetic joint infections. *J Antimicrob Chemother* 2014;69:5-10.
- Bozic KJ, Kurtz SM, Lau E, Ong K, Chiu V, Vail TP: The epidemiology of revision total knee arthroplasty in the United States. *Clin Orthop Relat Res* 2010;468:45-51.
- Bozic KJ, Kurtz SM, Lau E, Ong K, Vail TP, Berry DJ: The epidemiology of revision total hip arthroplasty in the United States. *J Bone Joint Surg Am* 2009;91:128-133.
- Tsukayama DT, Estrada R, Gustilo RB: Infection after Total Hip Arthroplasty: A study of the treatment of one hundred and six infections. *J Bone Joint Surg Am* 1996; 78:512-523.
- Zimmerli W, Trampuz A, Ochsner PE: Prosthetic-joint infections. *N Engl J Med* 2004;351:1645-1654.
- Kurtz S, Ong K, Lau E, Mowat F, Halpern M: Projections of primary and revision hip and knee arthroplasty in the United States from 2005 to 2030. *J Bone Joint Surg Am* 2007;89:780-785.
- Edwards JR, Peterson KD, Mu Y, et al: National healthcare safety network (NHSN) report: Data summary or 2006 through 2008, issued December 2009. *Am J Infect Control* 2009;37:783-805.
- Sculco TP: The economic impact of infected total joint arthroplasty. *Orthopedics* 1995; 18:871.
- Kurtz SM, Lau E, Watson H, Schmier JK, Parvizi J: Economic burden of periprosthetic joint infection in the United States. *J Arthroplasty* 2012;27:61-65.
- Barillo DJ, Marx DE: Silver in medicine: A brief history BC 335 to present. *Burns* 2014;40:S3-S8.
- Galli MM, Protzaman NM, Brigido SA: Utilization of silver hydrogel sheet dressing on postsurgical incisions: A pilot surgery in foot and ankle surgery. *Foot Ankle Spec* 2013;6:422-433.
- Krieger BR, Davis DM, Sanchez JE, et al: The use of silver nylon in preventing surgical site infections following colon and rectal surgery. *Dis Colon Rectum* 2011;54: 1014-1019.
- Schwartz J, Goss S, Facchin F, et al: A prospective two-armed trial assessing the efficacy and performance of a silver dressing used postoperatively on high-risk, clean surgical wounds. *Ostomy Wound Manage* 2014;60:30.
- Siah CJ, Yatim J: Efficacy of a total occlusive ionic silver-containing dressing combination in decreasing risk of surgical site infection: An RCT. *J Wound Care* 2011;20:561-568.
- Connery SA, Doens KL, Young C: A retrospective study evaluating silver-impregnated dressings on cesarean wound healing. *Adv Skin Wound Care* 2012;25: 414-419.
- Abboud EC, Legare TB, Settle JC, et al: Do silver-based wound dressings reduce pain? A prospective study and review of the literature. *Burns* 2014;40:S40-S47.
- Cai J, Karam JA, Parvizi J, Smith EB, Sharkey PF: Aquacel surgical dressing reduces the rate of acute PJI following total joint arthroplasty: A case-control study. *J Arthroplasty* 2014;29:1098-1100.
- Keats AS: The ASA classification of physical status—A recapitulation. *Anesthesiology* 1978;49:233-236.
- Parvizi J, Zmistowski B, Berbari EF, et al: New definition for periprosthetic joint infection: From the Workgroup of the musculoskeletal infection society. *Clin Orthop Relat Res* 2011;469:2992-2994.
- Pulido L, Ghanem E, Joshi A, Purtill JJ, Parvizi J: Periprosthetic joint infection: The incidence, timing and predisposing factors. *Clin Orthop Relat Res* 2008;466:1710-1715.
- Galat DD, McGovern SC, Larson DR, Harrington JR, Hanssen AD, Clarke HD: Surgical treatment of early wound complications following primary total knee arthroplasty. *J Bone Joint Surg Am* 2009; 91:48-54.
- Hopper GP, Deakin AH, Crane EO, Clarke JV: Enhancing patient recovery following lower limb arthroplasty with a modern wound dressing: A prospective, comparative audit. *J Wound Care* 2012;21:200-203.
- Tande AJ, Patel R: Prosthetic joint infection. *Clin Microbiol Rev* 2014;27:302-345.
- Biring GS, Kostamo T, Garbuz DS, Masri BA, Duncan CP: Two-stage revision arthroplasty of the hip for infection using an interim articulated Prostalac hip spacer. *Bone Joint J* 2009;91:1431-1437.
- Mahmud T, Lyons MC, Naudie DD, MacDonald SJ, McCalden RW: Assessing the gold standard: A review of 253 two-stage revisions for infected TKA. *Clin Orthop Relat Res* 2012;470:2730-2736.
- Backe H, Wolff D, Windsor R: Total knee replacement infection after 2-stage re-implantation. *Clin Orthop* 1996;331: 125-131.
- Darouiche RO: Treatment of infections associated with surgical implants. *N Engl J Med* 2004;350:1422-1429.